



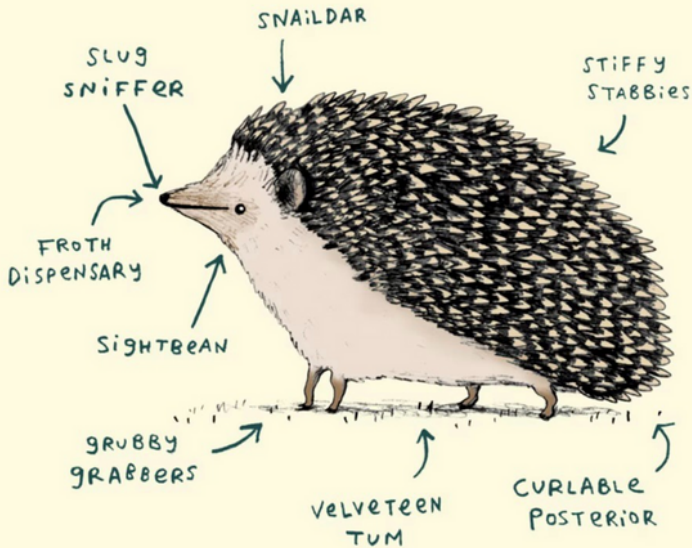
LET'S TALK ABOUT
APH ANATOMY
CONTENT
WARNING!!!

AN APH CARE GUIDE

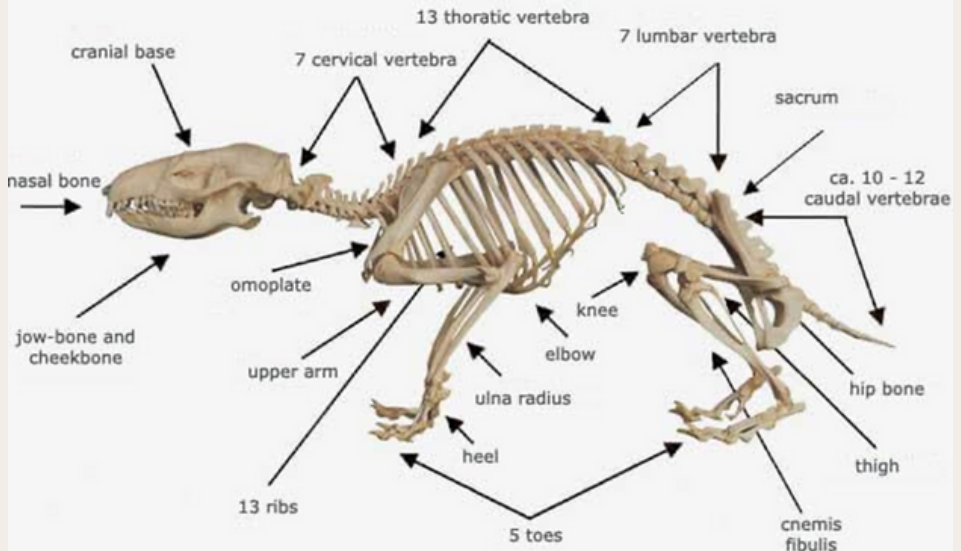
By Happy Quills

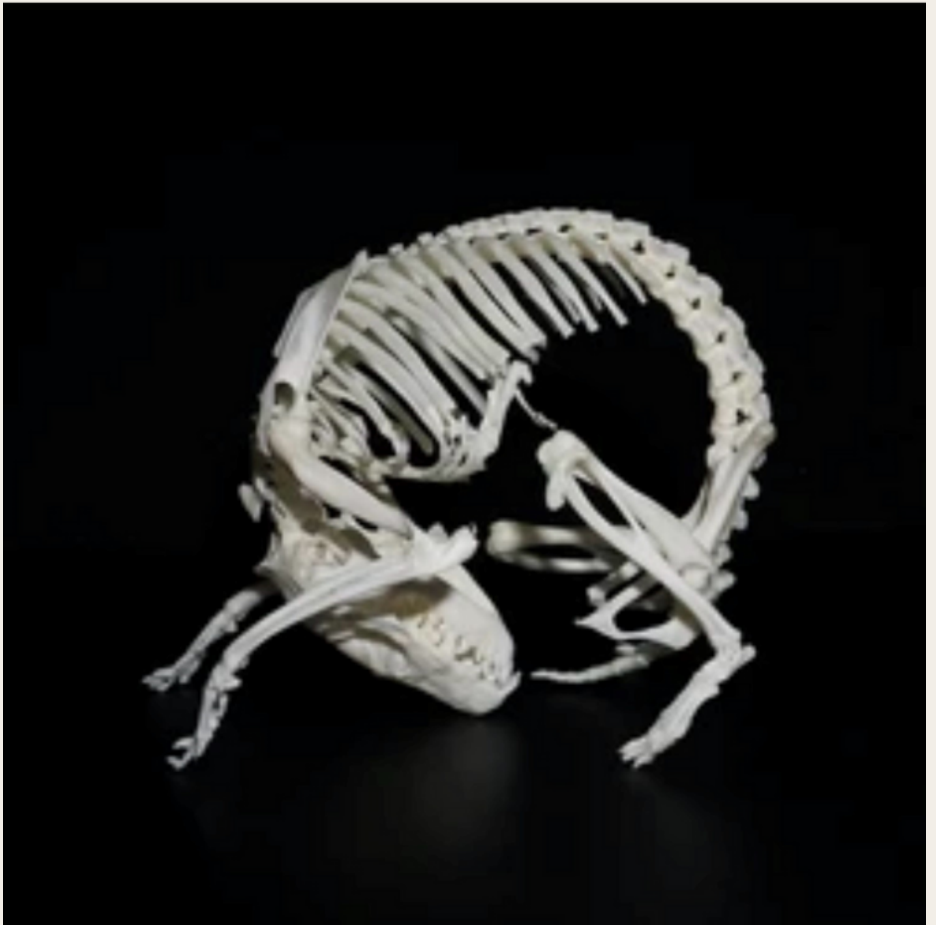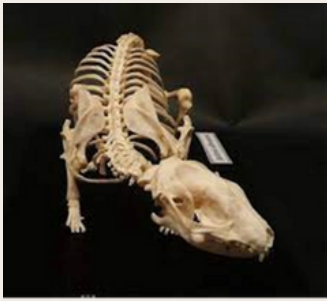WWW.HAPPYQUILLSRESCUEANDREHOMING.CO.UK

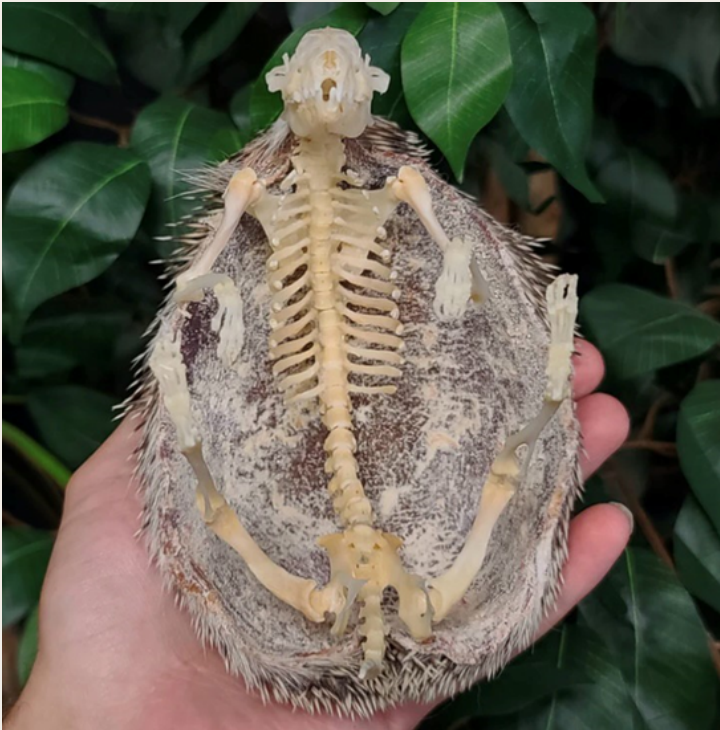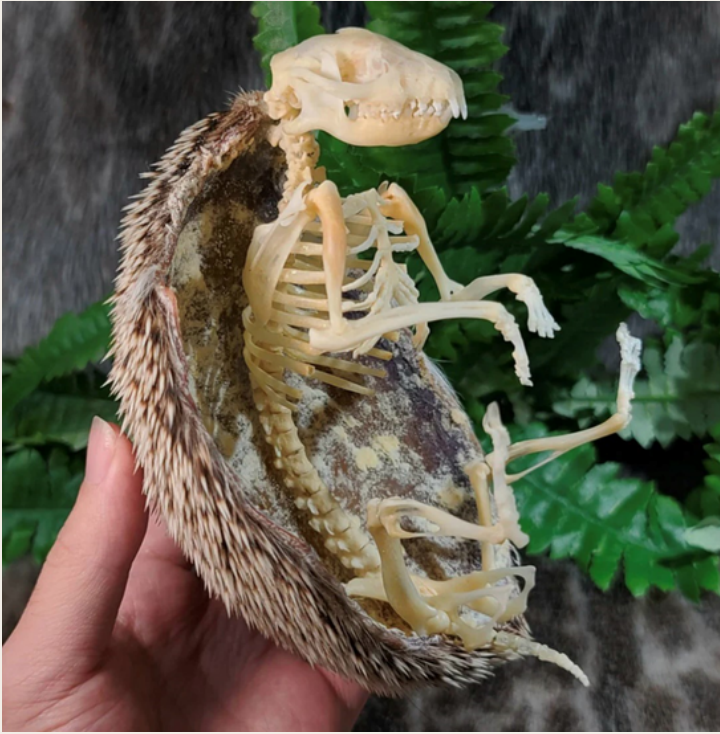ANATOMY OF A HEDGEHOG



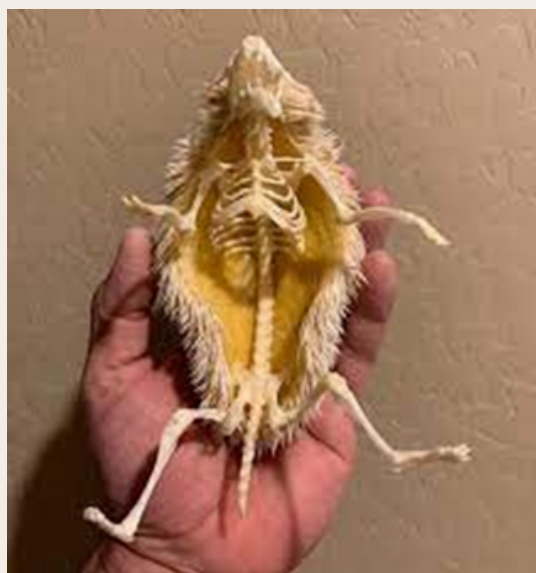HEDGEHOG SKELETON



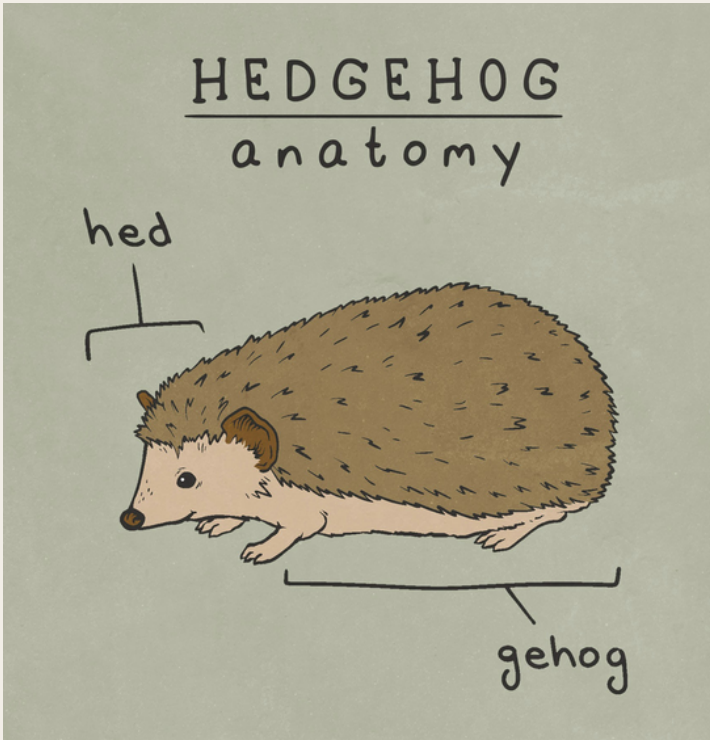


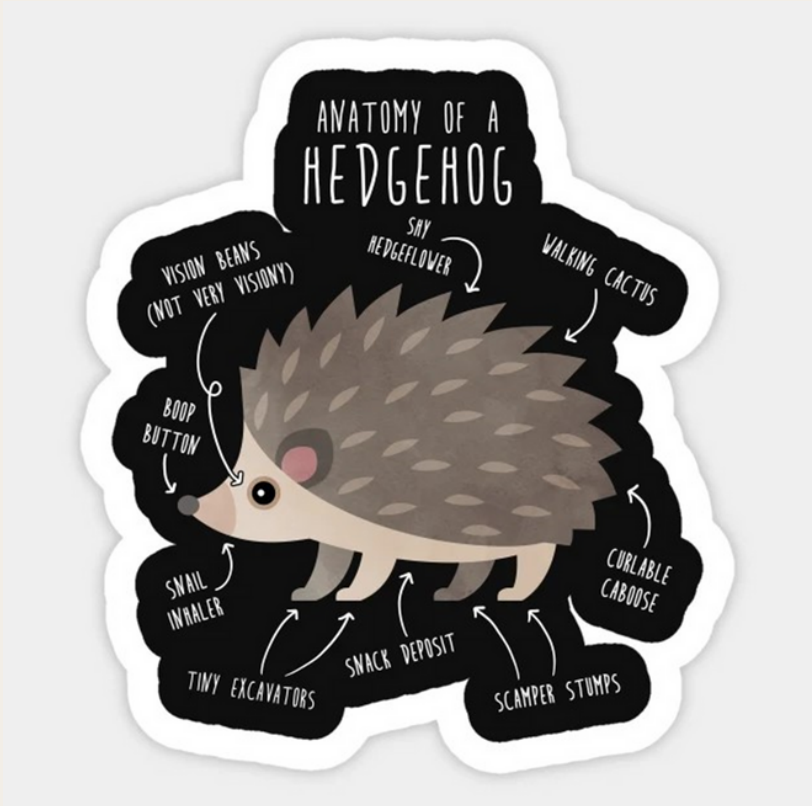





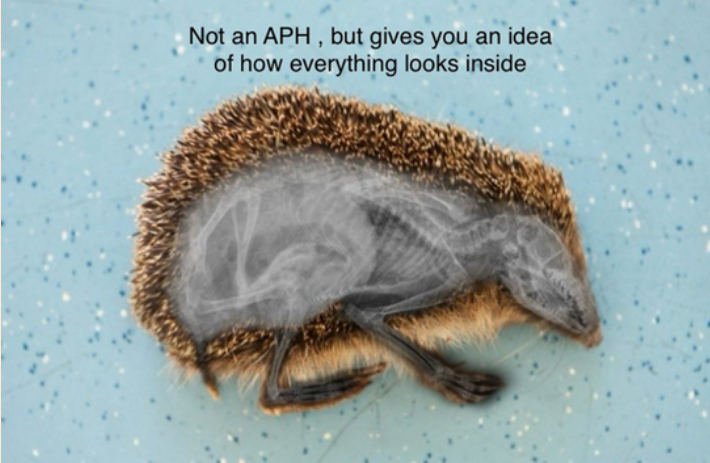SKULLS





XRAYs

Not an APH , but gives you an idea
of how everything looks inside



In case anyone wondered what a
hedgehog getting an X-ray looked
like



Hedgehogs are challenging patients to obtain radiographs due to their antipredator behavior of balling up, and the presence of dorsal spines controlled by a complex of muscles, that can obscure your radiographic view. Sedation or anesthesia is typically required to obtain diagnostic quality radiographs, with the exception of extremely depressed or moribund patients. Hair clips can be used to gently pull the dorsal spines out of the way. Pictured is an amelanistic (albino) African Pygmy Hedgehog (*Atelerix albiventris*) who is sedated for the purpose of taking radiographs.

